

Accuracy of OCT-based FFR in Identifying Hemodynamic Significance of Coronary Stenosis

Shengxian Tu¹, Wei Yu¹, Jiayue Huang¹, Dean Jia², Shaoliang Chen³,
Owen C. Raffel⁴, Daixin Ding¹, Feng Tian⁵, Jing Kan³, Su Zhang¹,
Fuhua Yan⁷, Yundai Chen⁵, Hiram Bezerra⁶, William Wijns⁸

¹Med-X Research Institute, Shanghai Jiao Tong University, Shanghai, China; ²Department of Cardiology, Beijing Anzhen Hospital, Capital Medical University, Beijing, China; ³Division of Cardiology, Nanjing First Hospital, Nanjing Medical University, Nanjing, China; ⁴Department of Cardiology, Prince Charles Hospital, Queensland, Australia; ⁵Department of Cardiology, Chinese PLA General Hospital, Beijing, China; ⁶Harrington Heart & Vascular Institute, University Hospitals Cleveland Medical Center, Cleveland, Ohio, USA; ⁷Department of Radiology, Ruijin Hospital, Shanghai Jiao Tong University School of Medicine, Shanghai, China; ⁸The Lambe Institute for Translational Medicine and Curam, National University of Ireland, Galway, and Saolta University Healthcare Group, Galway, Ireland.

Speaker's name : Shengxian Tu

I have the following potential conflicts of interest to declare:

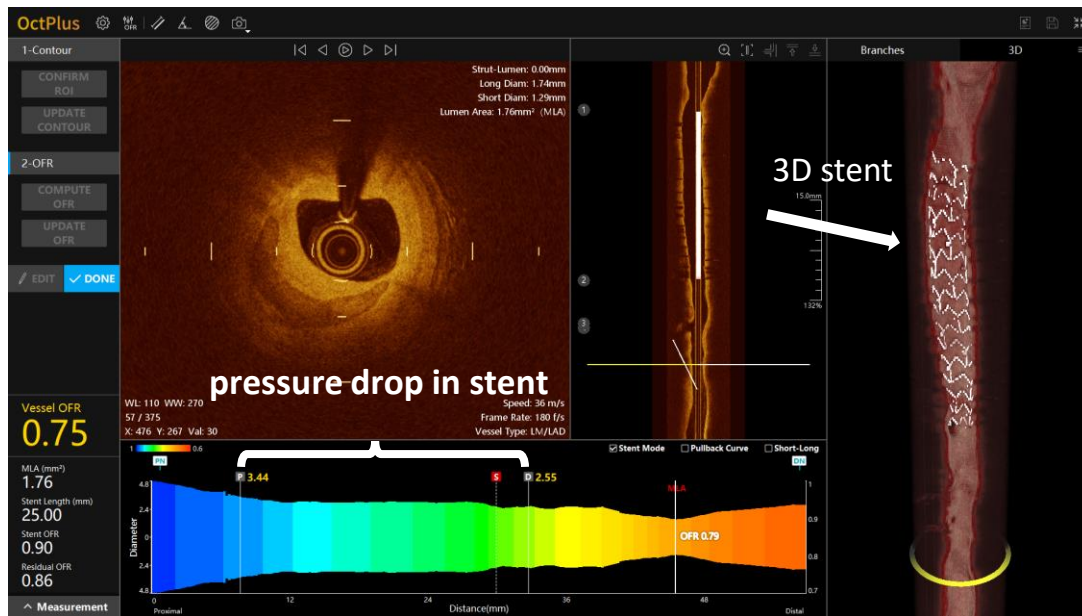
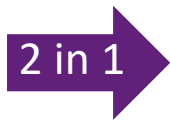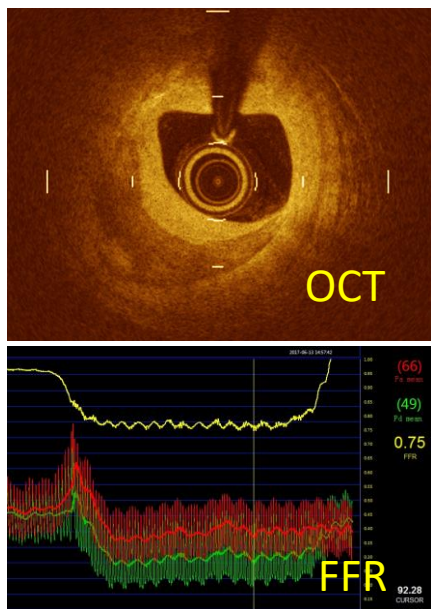
Receipt of grants / research supports: Medis medical imaging systems,
Pulse medical imaging technology

Why OFR (OCT-based FFR)?

To assess both plaque morphology and coronary physiology

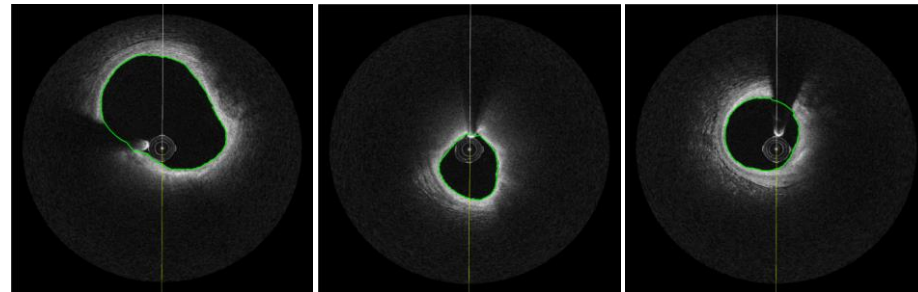
2 procedures
2 separate instrumentations

1 procedure and instrumentation
OCT + computed FFR



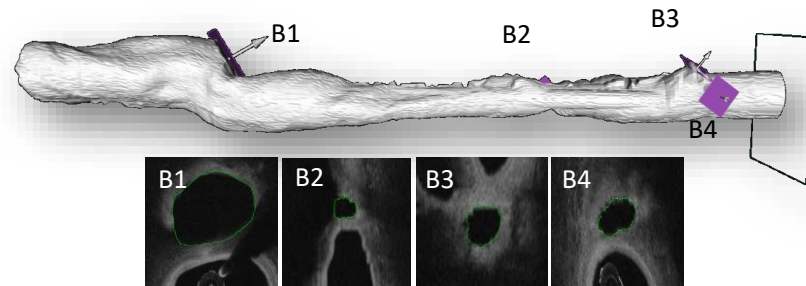
OCT co-registered OFR

1. Automatic OCT lumen contour delineation and 3D reconstruction

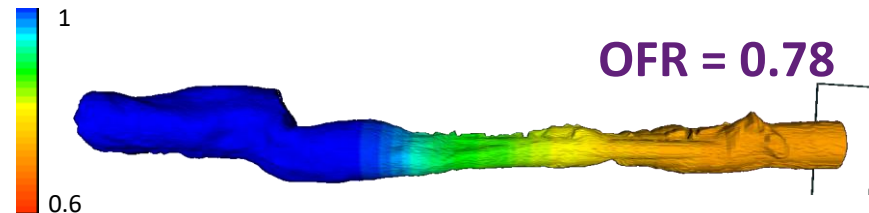


2. Automatic reconstruction of cut-planes at the side branches ostia

- (post-PCI only) AI-based automatic stent detection and reconstruction



3. Compute OFR using a novel algorithm



Contouring




Side branch



Stent detection



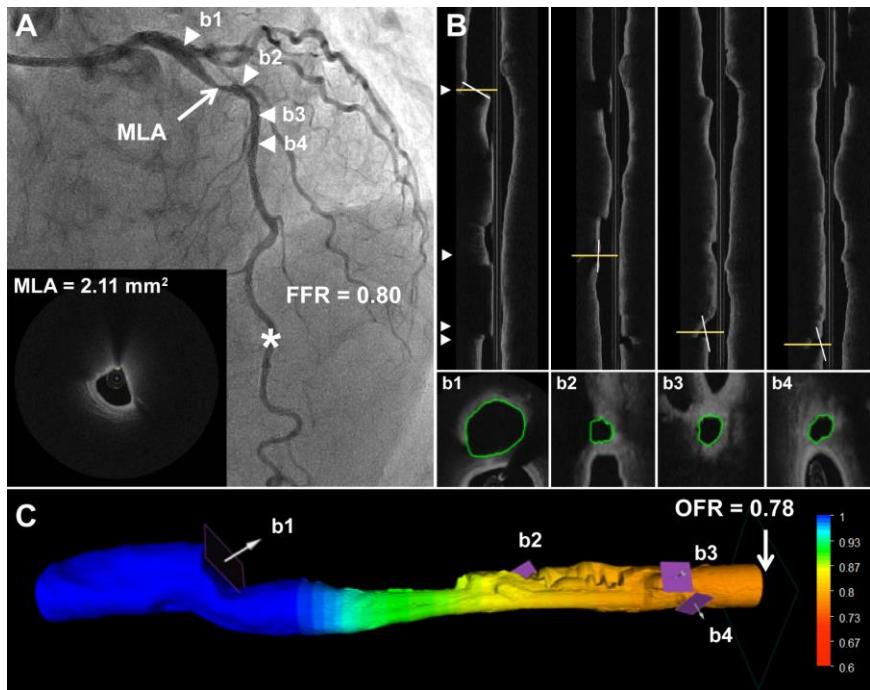
Compute OFR



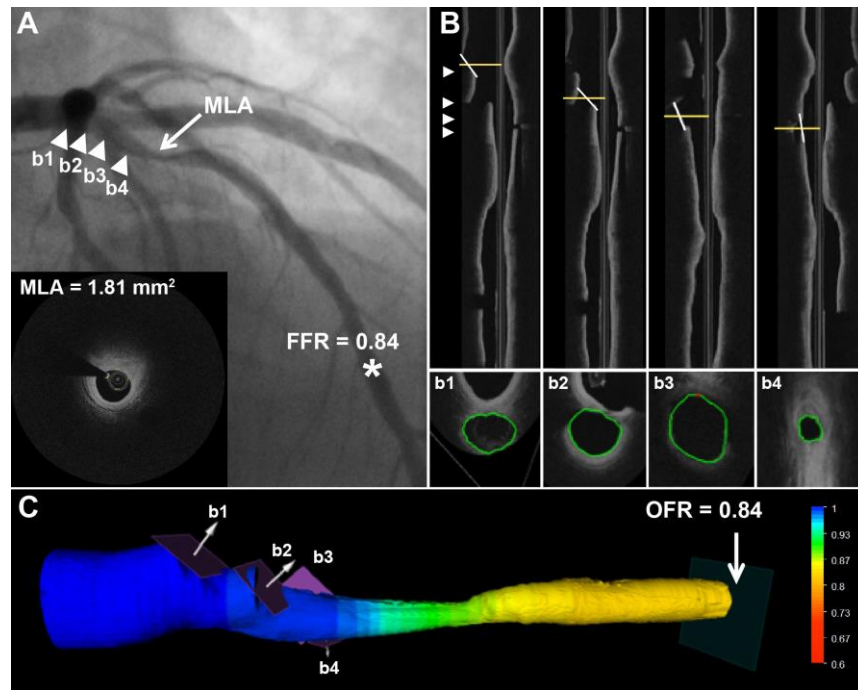
Analysis time
< 1 min

The screenshot displays the OctPlus software interface. On the left, a vertical toolbar contains buttons for '1-Contour' (with sub-buttons 'CONFIRM RO', 'UPDATE CONTOUR'), '2-OFR' (with sub-buttons 'COMPUTE OFR', 'UPDATE OFR'), and 'EDIT'/'DONE'. The main window shows patient information: Date: 18991230, Series Number: 0, Patient Name: Anonymous, Patient ID, Gender: O, Birthday: 18991230. Technical parameters include WL: 110, WW: 270, 0 / 0, X: 0, Y: 0, Val: 0. A central 'OctPlus' dialog box shows a progress bar and 'Computing...'. The right panel displays 'Long Diam: N/Amm', 'Short Diam: N/Amm', and 'Lumen Area: N/Amm²'. At the bottom right, it shows 'Speed: 36 m/s', 'Frame Rate: 180 f/s', and 'Vessel Type: LM/LAD'. The bottom of the screen features a graph with 'Diameter' on the y-axis and 'Distance(mm)' on the x-axis, ranging from 0 (Proximal) to 1 (Distal). A 'Short-Long' checkbox is visible in the bottom right corner.

Representative cases of OFR analysis



Case 1



Case 2

Study design

- Retrospective, multicenter, and observation study to evaluate the diagnostic accuracy of OFR, using FFR as the reference standard
- Post-hoc analysis of patients with at least 1 vessel underwent both OCT and FFR evaluation prior to any intervention
- The OFR analysts were blinded to the FFR data
- Intra- and inter-observer variability of OFR

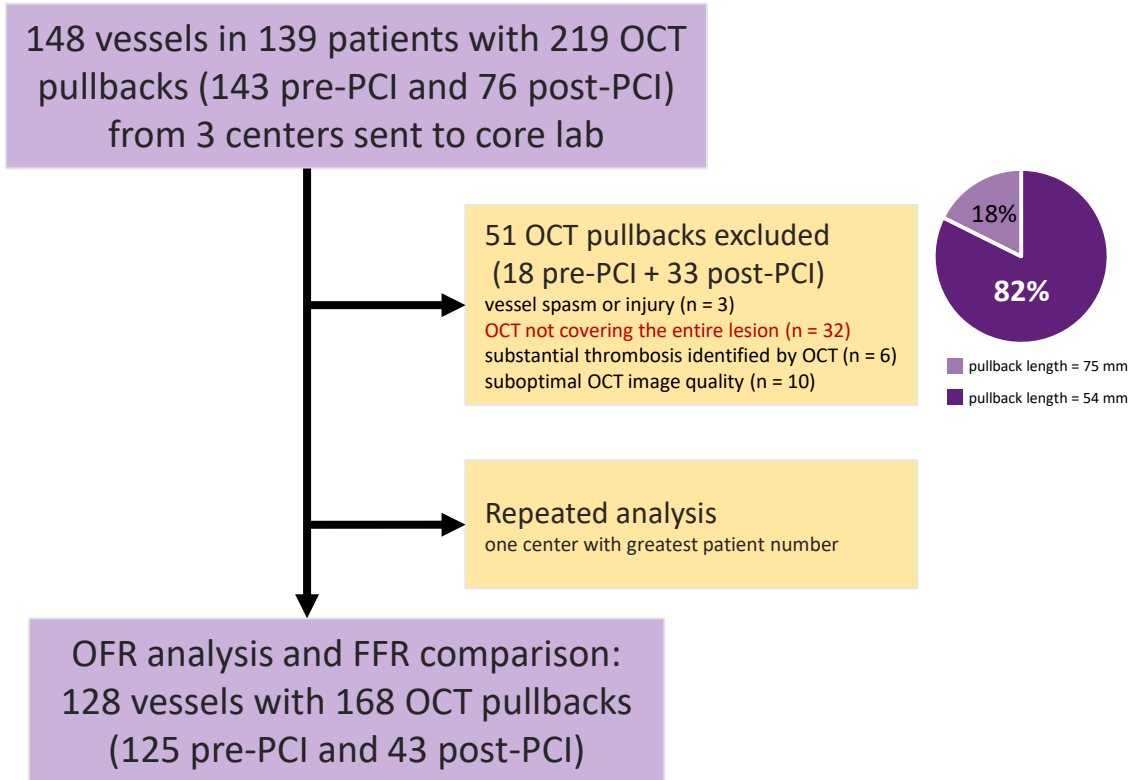
Core lab exclusion criteria

- Presence of vessel spasm or injury during OCT imaging
- OCT not covering the entire lesion
- Myocardial bridge in the interrogated vessels
- Substantial thrombosis identified by OCT
- Suboptimal OCT image quality

Data were provided by:

- University Hospitals Cleveland Medical Center, Cleveland, Ohio, USA
- Nanjing First Hospital, Nanjing, China
- Prince Charles Hospital, Queensland, Australia

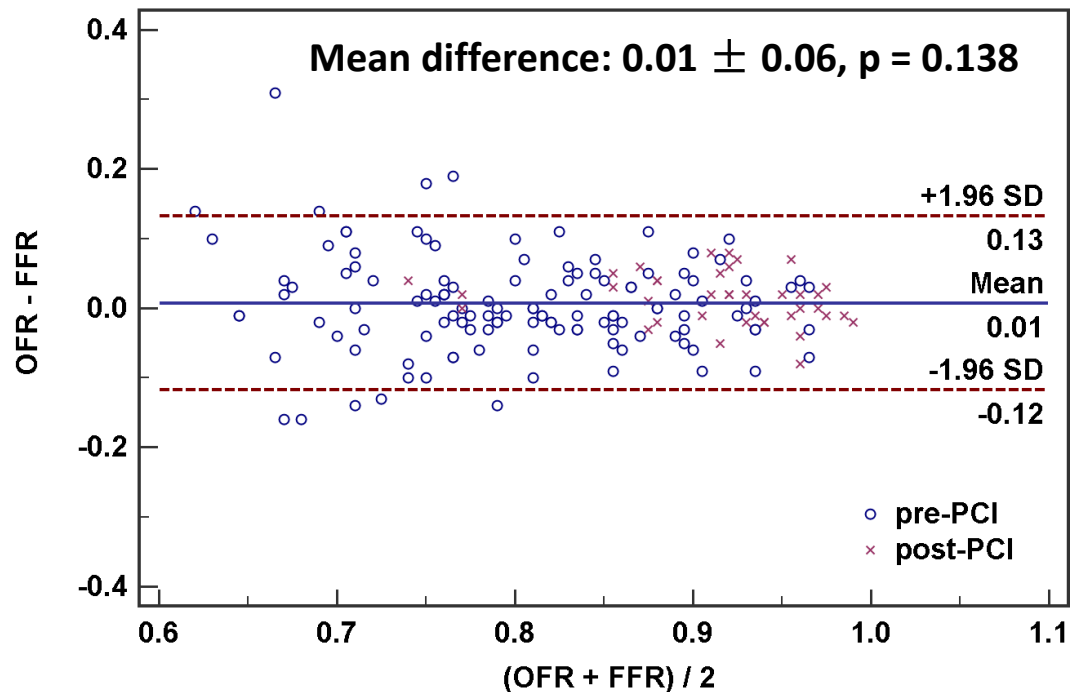
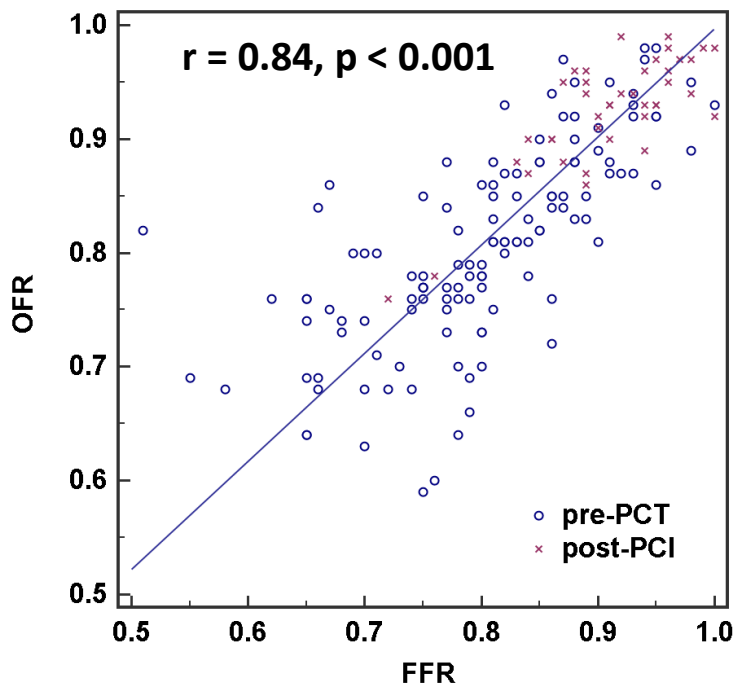
OFR analysis was performed at CardHemo, Med-X Research Institute, Shanghai Jiao Tong University, using a recently developed software (OctPlus, Pulse medical imaging technology, Shanghai).



Patients (n = 118, pre-PCI)	
Age, years	64.4 ± 10.2
Male	83 (70.3%)
Hypertension	101 (85.6%)
Hyperlipidemia	78 (66.1%)
Current smoker	39 (33.1%)
Diabetes mellitus	35 (29.7%)
Angina type	
Stable angina	53 (44.9%)
Unstable angina	29 (25.6%)
Silent ischemia	16 (13.6%)
Other	20 (16.9%)
Cardiovascular history	
Previous myocardial infarction	26 (22.0%)
Previous PCI	27 (22.9%)

Vessels (n = 125, pre-PCI)	
Lesion location	
Left anterior descending artery	78 (60.9%)
Left circumflex artery	18 (14.1%)
Obtuse marginal branch	1 (0.8%)
Right coronary artery	31 (24.2%)
Fraction flow reserve	
Mean ± SD	0.80 ± 0.09
Median [IQR]	0.80 [0.75, 0.87]
Minimum lumen area, mm²	1.83 [1.39, 2.52]
Bifurcation lesions	69 (55.2%)
Tandem lesions	68 (54.4%)

Correlation and agreement between OFR and FFR



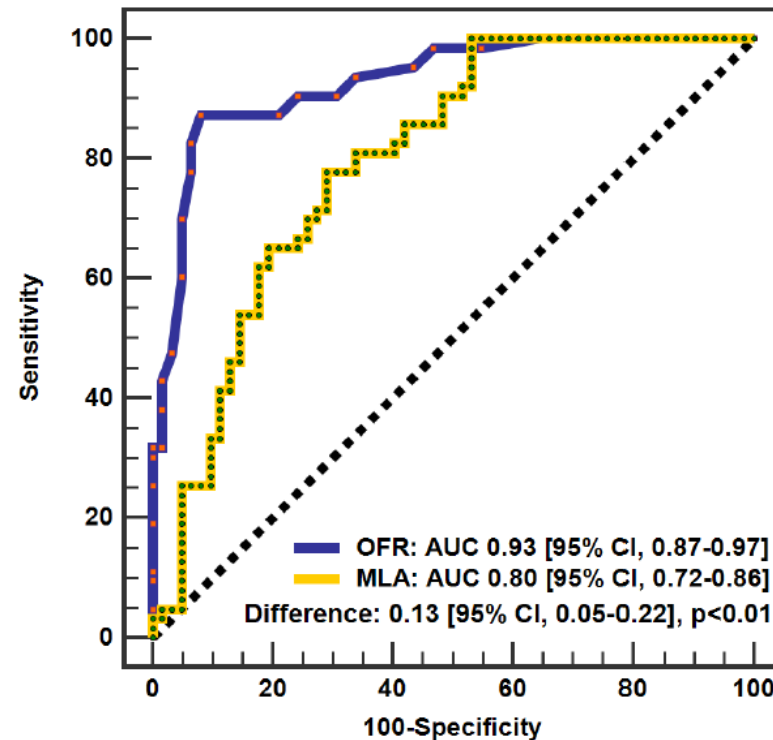
Diagnostic performance (125 vessels, pre-PCI)

	OFR ≤ 0.80	MLA $\leq 1.89 \text{ mm}^2$
Accuracy, %	90 (84-95)	74 (67-82)
Sensitivity, %	87 (77-94)	78 (66-87)
Specificity, %	92 (82-97)	71 (58-82)
LR+	10.8 (4.6-25.2)	2.7 (1.8-4.0)
LR-	0.1 (0.1-0.3)	0.3 (0.2-0.5)
PPV, %	92 (82-97)	73 (61-83)
NPV, %	88 (77-95)	76 (63-86)

Repeated OFR analysis variation

	Intra-observer	Inter-observer
MLA, mm ²	0.01 \pm 0.06	0.03 \pm 0.13
OFR	0.00 \pm 0.02	0.00 \pm 0.03

OFR has better diagnostic accuracy than OCT-MLA



Diagnostic accuracy of intracoronary optical coherence tomography-derived fractional flow reserve for assessment of coronary stenosis severity



Wei Yu¹, BSc; Jiayue Huang¹, BSc; Dean Jia², MD; Shaoliang Chen³, MD, PhD; Owen Christopher Raffel⁴, MB, ChB; Daixin Ding¹, BSc; Feng Tian⁵, MD; Jing Kan³, MBBS; Su Zhang¹, PhD; Fuhua Yan⁶, MD; Yundai Chen⁵, MD; Hiram G. Bezerra⁷, MD, PhD; William Wijns⁸, MD, PhD; Shengxian Tu^{1*}, PhD

1. Med-X Research Institute, School of Biomedical Engineering, Shanghai Jiao Tong University, Shanghai, China; 2. Department of Cardiology, Beijing Anzhen Hospital, Capital Medical University, Beijing, China; 3. Division of Cardiology, Nanjing First Hospital, Nanjing Medical University, Nanjing, China; 4. Cardiology Program, The Prince Charles Hospital and University of Queensland, Queensland, Australia; 5. Department of Cardiology, Chinese PLA General Hospital, Beijing, China; 6. Department of Radiology, Rui Jin Hospital, Shanghai Jiao Tong University School of Medicine, Shanghai, China; 7. Harrington Heart & Vascular Institute, University Hospitals Cleveland Medical Center, Cleveland, OH, USA; 8. The Lambe Institute for Translational Medicine and Curam, National University of Ireland, Galway, and Saolta University Healthcare Group, Galway, Ireland

Pre-PCI data are
published in
EuroIntervention

